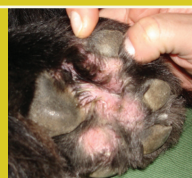

# PUFAs in clinical practice

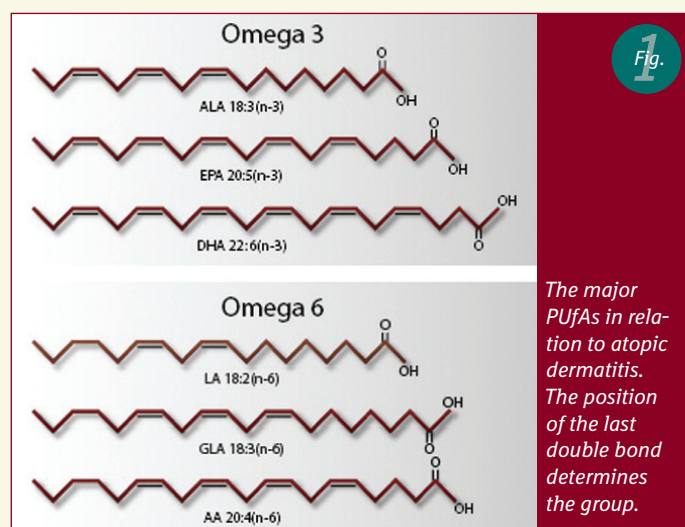
Lene Boysen, DVM, PhD



Polyunsaturated fatty acids (PUFAs) have been used in the treatment of allergic skin diseases since the mid-1980's. Other areas of application, such as claw diseases and seborrhea, have emerged since the mid 80's and today fatty acids are an important aid in the treatment of skin diseases.

Omega-3 and omega-6 fatty acids are of particular interest as they can not be synthesized by mammals. Dogs and cats therefore have to obtain these through food, as oral supplements or fatty acid-rich diets. In skin, fatty acids play an essential role in the maintenance of normal skin functions.

The most important PUFAs within the omega-3 group are alpha-linolenic acid (ALA) which is found i.e. in rapeseed oil and flax oil, and eicosapentaenoic acid (EPA) and docosahexaenoic acid (DHA) both of which are primarily found in marine oils (Figure 1).



The most important PUFAs within the omega-6 group are linoleic acid (LA) found in many vegetable oils, gamma-linolenic acid (GLA) found in evening primrose oil and borage oil and arachidonic acid (AA) mostly found in meat (Figure 1).

The beneficial effect of the PUFAs is thought to be due to their influence in balancing pro- and anti-inflammatory mediators. It may also be that they modulate the inflammatory response in immune mediated inflammatory conditions such as atopic dermatitis, and thereby reduce clinical sign severity.

Alterations of the skin lipids are believed to play an essential role in the pathogenesis of atopic dermatitis. PUFAs, by improving the skin barrier, may reduce the harmful changes of the outmost skin layers that occur in this disease.

Furthermore, acting as antioxidants, the PUFAs may reduce the negative impact of free radicals and oxidants released from inflammatory cells during an allergic reaction.

PUFAs have to be administered for several weeks (6-12 weeks) before a clinical effect can be expected. A maintenance dosage may subsequently be given.

The application of fatty acids in medical treatment will be described in the following. Skin disorders in which PUFAs have shown a clinical effect will be presented. The aetiology, clinical signs, diagnosis and treatment options of each disease will briefly be described with the effect of the PUFAs.

## Areas of application

### Canine atopic dermatitis

Canine atopic dermatitis (CAD) is an allergic skin disease of multifactorial aetiology affecting around 10% of the dog population. A familial background is seen, indicating a genetic predisposition.

House dust mites and pollens are among the most common allergens involved. They are thought to enter the body by inhalation or through the skin, inducing an allergic reaction.

*The incidence is higher among some breeds e.g.*

- Labrador
- Retrievers
- Boxers
- West Highland white terriers.

## PUFAs in clinical practice

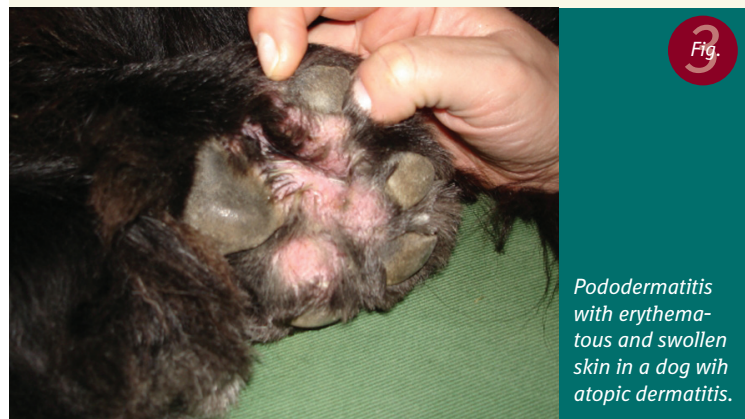Clinical signs begin between 1 and 3 years of age in about 70% of dogs with CAD. Pruritus is the main symptom and is most commonly observed in the face (Figure 2), on the legs and feet (Figure 3), in the axillary region and in the groin area (Figure 4). Pruritus may be seasonal or non-seasonal, depending on the allergens involved.

Otitis externa and conjunctivitis may be seen in 40-80% of the cases.



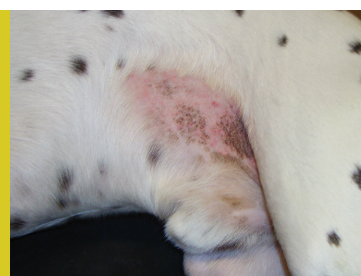
*Erythema around the lips of a dog with atopic dermatitis.*

Many dogs have a recurrent bacterial pyoderma due to *Staphylococcus intermedius* or infection due to *Malassezia pachydermatis*, as the skin of allergic patients is prone to these infections.



*Pododermatitis with erythematous and swollen skin in a dog with atopic dermatitis.*

Skin lesions are sometimes subtle and may be just a slight erythema. Excoriations and alopecia however often



*Erythema and papules in the groin of a dog with atopic dermatitis.*

develop at the sites of pruritus. Signs of secondary bacterial and yeast infections with pustules, collarettes and erythema soon develop.

The diagnosis atopic dermatitis is made based on history, clinical findings and exclusion of differential diagnosis such as parasitic disease and food allergy.

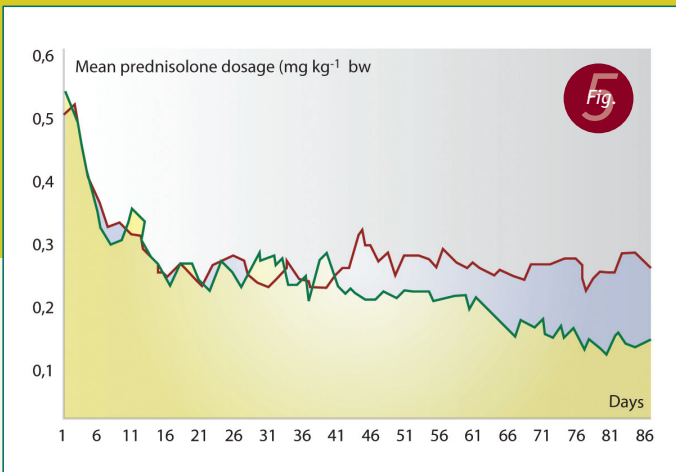
Among the treatment options are immunotherapy and symptomatic treatment.

An intradermal skin test can be carried out or allergen specific IgE can be measured in serum to select allergens for immunotherapy .

For symptomatic treatment, a variety of combination treatments are possible and can include glucocorticosteroids, topical treatments, antihistamines and essential fatty acids. Immunomodulating drugs such as cyclosporine are also available. Control of the secondary infections is a prerequisite for success.

### ***A case from practice***

The Dalmatian, Bobby, in figure 4 had a recurrent bacterial infection in the groin area due to atopic dermatitis. He had been pruritic in the face, on the feet and in the groin area from the age of 2. After treatment with antibiotics pruritus decreased, but was still a problem. Bobby was 9 years old and a symptomatic treatment was therefore chosen. Oral prednisolon and fatty acids (Viacutan Plus®, Boehringer-Ingelheim) were administered for 3 months. The pruritus was after this controlled using a daily supplement of fatty acids and twice weekly treatment with low-dosage prednisolon.



The mean dose of prednisolone in mg per kg body weight received by the active group (n=28) (■) and the placebo group (n=29) (●) in the test period (day 1 to 84).

Reprinted from Bente Særik "A randomized controlled study to evaluate the steroid-sparing effect of essential fatty acid supplementation in canine atopy." *Veterinary Dermatology* 2004, 15, pg. 137-145. Courtesy of Blackweel Publishing Ltd.

### The effect of PUFAs in CAD

A controlled, blind clinical trial carried out in 2004 showed that PUFAs have a steroid-sparing effect in dogs with atopic dermatitis<sup>1</sup>. In figure 5 it can be seen that the combination of PUFAs with steroid reduces the dosage of steroid required to control the pruritus. After 64 days of treatment, the difference between the group of dogs receiving fatty acids and steroids and those receiving placebo and steroids is statistically significant.

Several other studies have demonstrated a positive effect of PUFAs as a supplement in the treatment of canine atopic dermatitis<sup>2,3</sup>.

### Feline atopic dermatitis

Atopic dermatitis (AD) is an important cause of pruritus in cats. Some of these cats also show signs of respiratory disease. Up to 73% of the cats with allergy have AD. No predisposition by specific breeds has been demonstrated.

There are however reports of a familial involvement in feline AD, suggesting a genetic component.

Milliary dermatitis, "head and neck pruritus", self induced alopecia (Figure 6) and eosinophilic plaque are among the clinical manifestations of the disease. Combinations of these patterns have been observed. The cutaneous reaction pattern of military dermatitis consists of papules and small crusts which can be all over the body, particularly on the head, neck and trunk. Eosinophilic plaques can vary in size and may have an eroded surface or secondary crusts. These plaques are often observed at the neck, medial thigh, and the abdominal skin. Exclusion of differential diagnosis such as food allergy, dermatofytosis, parasitic diseases and flea allergy are important elements in the diagnostic work-up.

**The diagnosis atopic dermatitis is made on the**

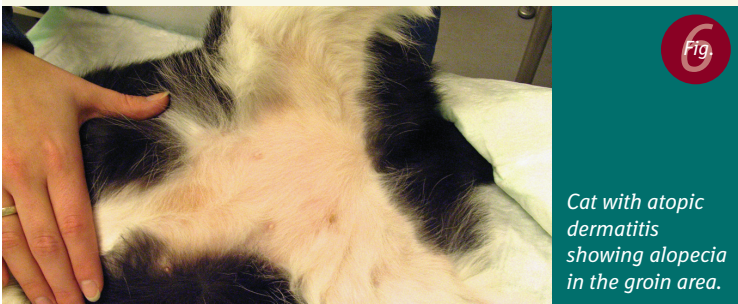
- basis of a history of pruritus
- clinical findings
- response to corticosteroids
- the histopathological pattern

The therapy options are immunotherapy or symptomatic treatment. In order to select allergens for immunotherapy an intradermal skin test or a measurement of allergen-specific IgE in serum can be done.

Glucocorticoids, antihistamins and essential fatty acids are available for symptomatic treatment.

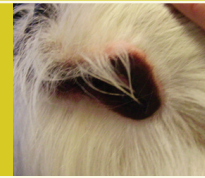### A case from practice

Nala, a seven year old domestic short hair cat, had been licking her belly for many years. Lately she had started to lick the hind legs as well. Marked alopecia was noted at the ventral part of the body, and especially the groin and inner thighs were without hair (Figure 6). After exclusion of differential diagnosis, the diagnosis atopic dermatitis was made. The cat was prescribed symptomatic therapy with antihistamines, fatty acids and dexamethasone. The pruritus disappeared and within a couple of months a normal hair coat had returned. The cat was then kept on a maintenance dosage of all three therapeutics.



Cat with atopic dermatitis showing alopecia in the groin area.

Courtesy of Mette Schærf DVM



### The effect of PUFAs in feline AD

PUFAs have shown to be effective in the treatment of cats suffering from flea bite hypersensitivity and atopy<sup>4-6</sup>. A significant reduction in the presence of crusted papules has been reported in cats with miliary dermatitis<sup>4</sup>. The studies indicate that 50-75% of treated cats respond well to the fatty acids. Furthermore, a synergistic effect of combining PUFAs with glucocorticoids and antihistamines has been reported<sup>7</sup>.

### Abnormal claw formation

#### *Symmetrical lupoid onychodystrophy*

When a claw disease is symmetrical and causes sloughing of the claw, followed by abnormal claw formation, it should be considered whether this is due to symmetrical lupoid onychodystrophy. Symmetric lupoid onychodystrophy is a claw disorder, which is seen in dogs with e.g. food hypersensitivity or a drug reaction. The disease may also be idiopathic.

Lupoid onychodystrophy is seen in dogs.

The German shepherd dog seems to be particularly predisposed to this. Most dogs suffering from lupoid onychodystrophy are between 3 to 8 years of age and otherwise healthy. They develop claw abnormalities usually on more than one foot. The claw separates from the claw bed and is sloughed off. It regrows as a deformed, short, dry and brittle claw (Figure 7). The dog may be lame and show pain on palpation. Secondary bacterial infection is often seen. Lupoid onychodystrophy diagnosis is confirmed using histopathology.

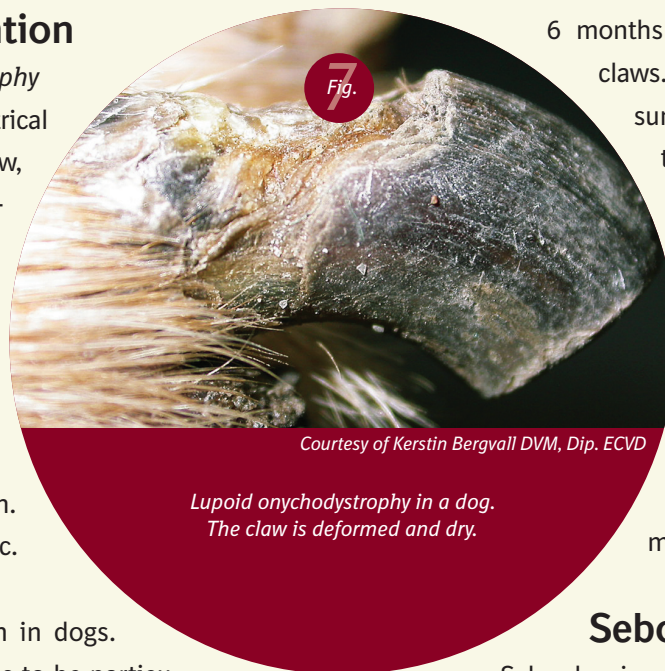PUFAs are among the few treatment options. Clinical studies have demonstrated a beneficial effect of the fatty

acids after 2-3 months of treatment<sup>8,9</sup>. When treatment stops, relapses are usually seen.

If fatty acids fail, treatment with tetracycline or doxycycline and niacinamide can be tried. Glucocorticoids may also have a beneficial effect.

### A case from practice

The 5 year old male miniature Schnauzer, Asterix, was presented to the clinic with deformed and dry claws. The claws of almost all toes had sloughed off in the last 6 months and only two toes had original claws. They were brittle and had many fissures. The third phalanx of one of the toes was amputated and sent to the pathologist. A histopathological picture consistent with lupoid onychodystrophy was reported, confirming the clinical diagnosis. The dog was treated with fatty acids (Viacutan Plus®, Boehringer-Ingelheim), and after 2 months of treatment improvement of new claw quality was visible.



*Lupoid onychodystrophy in a dog.  
The claw is deformed and dry.*

*Courtesy of Kerstin Bergvall DVM, Dip. ECVD*

### Seborrhea sicca

Seborrhea is an inherited disorder of keratinisation or cornification of the skin. The rate of cell turn-over is increased, so that the skin is renewed within 8 days instead of the normal 21 days. Production of sebum is increased, sometimes giving a greasy skin and dull coat.

Primary seborrhea is most commonly seen in the American cocker spaniel, West Highland white terrier, Basset hound and English springer spaniel.

Secondary seborrhoea may develop in dogs with diseases such as food hypersensitivity, atopy or parasitic disease.

Dogs with seborrhea can have greasy, malodorous skin (seborrhoea oleosa) or a more dry and scaly skin (seborrhoea sicca), or a condition between the two. In some cases



coalescent, scaly or crusty pruritic patches are seen, indicating a seborrheic dermatitis. A ceruminous, hyperplastic otitis externa, digital hyperkeratosis and dry, brittle claws are other signs of seborrhea.

Dogs with seborrhea are prone to skin infections with bacteria and/or *Malassezia pachydermatis*, both of which may enhance pruritus.

Primary and secondary seborrhea cannot be clinically distinguished and the diagnosis primary seborrhoea is made by exclusion. Histopathological evaluation of skin biopsies may help in the diagnosis.

The treatment of primary seborrhea is directed at controlling the disorder. It cannot be cured. Antiseborrheic shampoos and moisturizers are among the treatment options. Corticosteroids are efficient in some cases. Secondary infections must be treated and re-infection avoided.

PUFAs have shown to have a beneficial effect on dogs with seborrhea sicca<sup>10</sup>, reducing the generalised dry scaling, and may be used as a supplement to other treatments. ■

## Final remarks

*In clinical practice, PUFAs have shown applicability in the treatment of several skin diseases, some of which have been described above. Atopic dermatitis in dogs and cats is a common and serious disease, and the fatty acids have shown great value in their management. Symmetrical lupoid onychodystrophy and seborrhea sicca are two diseases that can be very difficult to treat, and fatty acids may be an aid in their control. The PUFAs are probably applicable to many more diseases and reports of their effect are warranted in the future.*

Lene Boysen, DVM, PhD  
Clinic of Veterinary Dermatology  
Toftebæksvej 22  
DK-2800 Kgs. Lyngby  
Denmark  
E-mail: info@dyrlaegeboysen.dk  
Phone: +45 45 28 14 15  
Fax: +45 45 28 14 50

### References

1. Sævik BK, Bergvall K, Holm BR, et al. A randomized, controlled study to evaluate the steroid sparing effect of essential fatty acid supplementation in the treatment of canine atopic dermatitis. *Vet Dermatol* 2004, 15: 137-145
2. Abba C, Mussa PP, Vercelli A, et al. Essential fatty acids supplementation in different-stage atopic dogs fed on a controlled diet. *J Anim Physiology and Anim Nutrition* 2005, 89: 203-207.
3. Harvey RG. A blinded, placebo-controlled study of the efficacy of borage seed oil and fish oil in the management of canine atopy. *Vet Rec* 1999, 10: 405-407.
4. Harvey RG. A comparison of evening primrose oil and sunflower oil for the management of papulocrustous dermatitis in cats. *Vet Rec* 1993, 4: 571-573.
5. Harvey RG. Effect of varying proportions of evening primrose oil and fish oil on cats with crusting dermatosis ("miliary dermatitis"). *Vet Rec* 1993, 28: 208-211.
6. Miller WH Jr, Scott DW, Wellington JR. Efficacy of DVM Derm Caps Liquid in the management of allergic and inflammatory dermatoses of the cat. *J Am Anim Hosp Assoc* 1993, 29: 37-40.
7. Scott DW, Miller WH. The combination of an antihistamine (clorpheniramine) and an omega-3/omega-6 fatty acid-containing product (DVM Derm Caps Liquid) for the management of pruritic cats. *N Z vet J* 1995, 43: 29-31.
8. Bergvall K. Treatment of symmetrical onychomadesis and onychodystrophy in five dogs with omega-3 and omega-6 fatty acids. *Vet Dermatol* 1998, 9: 263-268.
9. Scott DW, Rouselle S, Miller WH Jr. Symmetrical lupoid onychodystrophy in dogs. A retrospective analysis of 18 cases (1989-1993). *J Am Anim Hosp Assoc* 1995, 31: 194-201.
10. Scott DW, Miller WH. Primary seborrhea in English springer spaniels: a retrospective study of 14 cases. *J Small Anim Pract* 1996, 37: 173-178.